



Patient Details

Name : Aupita Singh

Age / Gender : 2y / F

Father's Name : Madan Singh

Address : Pratapgarh, UP

Contact No :

POC / PCSC No.: 42/25

Diagnosis: RB

GENERA COUNSELLING

1. Accomodation.
2. Blood Donation.
3. 2% Betadine gaggles
4. Sitz Bath.
5. Thermometer.
6. fever charting
7. Danger Sign.
8. general hygiene.
9. Sick card.
10. No Vaccination | Immuni-zation

HH advice.

Helpline No:- 9810590067, 9868397536

Remarks :

PICC Line Care

अगर आपके बच्चे को PICC Line Care लगी हुई है तो डे केयर के डाक्टर या नर्स से ज़रूर संपर्क करें।

ब॰ रो॰ वि॰ कार्ड
O.P.D. Card

डा॰ राजेन्द्र प्रसाद नेत्र विज्ञान केन्द्र
अ॰ भा॰ आयु॰ सं॰, नई दिल्ली-110029

दृष्टि
नेत्र अमूल्य उपहार है जो आप ही दे सकते हैं

अनुभाग व दिन Section and Day	कमरा नंबर Cabin No.
बुधवार व शनिवार Wednesday & Saturday VI	

R. P. Centre (Eye Centre)

UHID: 108098760
Dept. No. 20250050013768
Clinic. No.:2025/RB/37
ARPITA SINGH 2Y/F
W/O: MADAN SINGH

Date: 12/02/2025 General
₹0
Retinoblastoma Dr. SR/JR
RB -VI- R.142B
Unit-VI
Room No.: 142

Address: dhema sadar jila allahabad, UTTAR PRADESH, INDIA
Mobile

का टंडन का एकक
ika Tandon's Unit

आयु Age	पता Address

दिनांक DATE	निदान DIAGNOSIS	उपचार Treatment
	MSG	RE Entire vitreous cavity mass filled with high spikes & calcifications.
	RE Extra-scleral extension (+)	LE Hetero genous mass at post pole @ optic disc with spikes & calcifications
	RE S/O Retinoblastoma	

कृपया इस कार्ड को सुरक्षित रखें तथा अस्पताल में दिखाने के समय हर वक्त साथ लायें।
Kindly keep this Card safely and bring it on your follow-up visits.

1. धूम्रपान निषेध 2. कूड़ा कर्कट केवल कूड़ेदान में ही डालें 3. थूकिये नहीं
1. No Smoking 2. Use Dustbin 3. No Spitting

OSG-81C

एम. आर. आई प्रपत्र 1 / MRI Form 1

दूरभाष सं. / Tel. No. :26593614
26546455

अखिल भारतीय आयुर्विज्ञान संस्थान / ALL INDIA INSTITUTE OF MEDICAL SCIENCES

एन.एम.आर. विभाग / DEPARTMENT OF N.M.R.

नैदानिक एम. आर. आई. माँग प्रपत्र / CLINICAL MRI REQUISITION FORM

1. Clinical Dept. or Unit ..... Pediatrics ..... Date of Requisition 05/04/25
   OPD No..... UHID No..... 10809876O ..... Ward / Bed No.....

2. Screening Dept. : Radio-Diagnosis ☐ Neuro-Radiology ☐ Cardiac Radiology ☐
   (Tick as appropriate)

3. रोगी का नाम /Patient's Name ..... Arpita Singh ..... आयु /Age 2y ..... लिंग /Sex Fem
   (साफ अक्षरों में / In Block letters)

   जन्म तिथि /Date of Birth : दिन /Day ..... माह /Month ..... वर्ष / Year ..... वजन /Weight ..... कि. ग्रा. /Kg.

4. General Patient Condition (Tick as appropriate)
   (i) Critical and with life support (ii) Ill but without life support (iii) Ambulatory

5. Clinical Details : History : K/c/o (Rt) EORB
   (Lt) IORB

   Examinations

   Relevant Investigations :

   Previous CT / MR / Other Reports / Studies (with numbers, if any) Received 2 cycles of chemotherapy.

6. Blood Urea / S Creatinine (Rt) EORB, (Lt) IORB

7. Clinical Diagnosis : .....

8. Exact Anatomical site for MRI : MRI Brain + Orbit.

9. Special Instructions (Sedation, Allergy or other details which may facilitate a safe and informative study).

10. (a) Contrast Enhancement Required : Yes ✓ No.....
    (b) Allergic to any drugs :
    (c) Implant in Body (Tick as appropriate)
    Cardiac Pacemaker .....Aneurysmal clips.....Cardiac Valve/Prosthesis.....
    Metallic Implants.....Sharpnel/Pellet.....Others.....None.....

Dr. RACHNA SETH
आचार्य / Professor
बालरोग चिकित्सा विभाग / Department of Pedia.
A.I.I.M.S., New Delhi-1100..

हस्ताक्षर / Signature .....
नाम / Name .....
(साफ अक्षरों में / In Block letters)
पदनाम / Designation .....

(Requisition may be signed by a Faculty Member/Sr. Resident)

एम.आर.-5 डाक्टर आर्डर
M.R.- 5 Doctors Orders

अखिल भारतीय आयुर्विज्ञान संस्थान, नई दिल्ली-110029
ALL INDIA INSTITUTE OF MEDICAL SCIENCES, NEW DELHI-110029

...all orders Cancel by crossing through and initaling Rewrite all orders when turning over and after major ...rations. Sister should sign in the column provided when the order is transferred to the treatment books.

...me Arpita. उम्र Age 2yr 8mo लिंग Sex F. वैवाहिक स्थिति Marital Status यू.एच.आई.डी. नं. UHID No.

...स/Service वार्ड/Ward बेड/Bed व्यवसाय/Occupation धर्म/Religion

Date Order	Date Cancelation	Doctor's orders with signature	The sister's signature with date
		S/B Derma SR/JR. (Dr Priyanka / Dr. Nidhi) - TD = 2 days O/b ~~[illegible]~~ ill defined erythema c̄ overlying grouped vesicle on b/l leg & dorsum of feet. K/c/o - Retinoblastoma on chemotherapy (Vincristine + etoposide + carboplatin) 1st cycle - 7/2/25 - 8/2/25 2nd " - 19/3/25 - 20/3/25 h/o fever since 22/3/25. ↳ erythema & swelling of b/l legs since 2 days Δsis :- ? Neutrophilic Sweets on D2 of Augmentin Inv: CBC, Pus C/S from vesicle **Adv** 1) ~~[illegible]~~ look for danger sign 2) Cont. syrup Augmentin (457/5ml) 2.5ml 3) Documentation of fever Remain in Skin OPD c̄ reports (3rd floor - 1 A wing). Nidhi	

05/04/25 (Rt) EORB
(Lt) IORB — Staging EUA pending
(Cancelled twice i/v/o LRTI).

No fresh complaints. Afebrile

Received cycle 4 HDCEV
↓
Reassessment pending.

O/E Pallor(+) HR-90/min Chest clear, NAD
RR-30/min CVS-S1S2 heard
CFT-2s NUS 3g ....

04/04/25
7.9 | 7140 | 960 | 540

Adv

1) MRI Brain + contrast leelns
2) EUA date → RPC consultation.
3) Sibling screening
4) N/V OPD → 09/04/25 Wednesday 9am
5) RB gene testing

28/3/25

Vitals:
T - N
PR - 132/mt
RR - 30/mt
BP - 111/93 mmHg
SPO_2 - 100%

- CBC, PCT } to be send
Pus c/s from vesicle

F.N. ?
FN - D_5

→ afebrile status
→ swelling/redness over b/l lower limb

imu?
Pct: 0.09 ng/ml
pus c/s: sterile
Blood c/s: sterile
LFT/RFT: (N)

Adv
1. rpt CBC
↓
if counts (N)
⇓
then stop iv antibiotics

2. ?

3. N/v in day care for f/u ?

f/u
(cbc)

3/4/25

29/3
7.9) 4230 (54×10³
30

FN: D10
Afebrile for 72 hours.
Blood c/s - sterile

Coulter ANC
> 200

7.5) 6690 (94000
Mixed - 12.6
Neu - 3.8%

- Abx stopped

Adv
- Check Coulter CBC.
Stop Abx if ANC ?
→ f/u c rpt CBC/?
on 5/4/25

08/04/25
(Co
No fresh
O/E
Adv
1) MRI
2) EUA
3) ?
4) N/V
5) ?

PHYSICAL EXAMIN
Resp.

किरण नैदानिक विभाग
अ० भा० आ० सं०, नई दिल्ली-११००२९
PARTMENT OF RADIODIAGNOSIS
A.I.I.M.S., NEW DELHI - 110029

RAY/CONTRAST STUDIES REQUISITION FORM

Date : 24/3/25

Ref. Deptt./Unit :

Age/Sex :

UHID No. :

LMP :

Outdoor / Casualty

Required :

and Examination :

cal / Working Diagnosis :

od Urea / S. Creatinine :
y h / o allergy or asthma :
or IVU patients only) :

Signature of Referring Physician / Date :

Consent :

I hereby give consent for the performance of any diagnostic or therapeutic radiological procedure with or without the use of contrast injection and / or sedation. The associated complications and risks have been explained to me.

nature of Patient / Date :

r appointment is on :

Room No. :

e Slot : 8:30 9:00 9:30 10:00 10:30 11:00

ay No. :

GOYAL MRI & DIAGNOSTIC CENTRE
B-1/12, SAFDARJUNG ENCLAVE, NEW DELHI - 110029
Phone : 011-40771234, 26107559 E-mail : goyalmri@yahoo.com

Dr. Ankur Gadodia
MD (AIIMS), DNB, FRCR

Dr. Pranay R Kapur
MBBS, DNB

BABY ARPITA SINGH, 2 YRS / F **UID: 04.25.631** **15.04.2025**

M.R. OF THE BRAIN AND ORBITS WITH CONTRAST

Axial T1, DWI and FSE T2 weighted scans of the brain were studied and these were correlated with coronal T2, fat sat T1 & T2 weighted scans including both orbits. Additional T1 weighted axial, coronal & sagittal scans were obtained following administration of contrast (10mL Omniscan). No immediate adverse contrast reaction was noted.

Follow up case of retinoblastoma, on chemotherapy. Previous scans are not made available for comparative evaluation.

Right phthisis bulbi is seen. Plaque like soft tissue is seen in the posterior chamber of the right globe. Right optic nerve is thinned out.

Left globe is normal in size. 12 x 18 mm focal lesion is seen in the posterior chamber of the left globe. There is associated retinal detachment and vitreous hemorrhage. Lesion shows hypointense signal on both T1 and T2 weighted images. There is heterogeneous enhancement following administration of contrast. Left optic nerve is unremarkable. Findings are suggestive of residual disease.

There is thickening of the gyri of the bilateral temporoparietal lobe with ill-defined interface of grey and white matter (R>L). Findings are suggestive of polymicrogyria pachygyria complex.

The optic chiasm, infundibulum and pituitary gland do not show abnormality.

Cerebral and cerebellar parenchyma is otherwise unremarkable. No acute infarct is seen on diffusion weighted images.

Bilateral basal ganglia and thalami are normal in signal intensity. The corpus callosum and skull base are normal. No midline shift is seen. No acute intracerebral hemorrhage. Posterior fossa and brainstem are unremarkable. Skull base arteries demonstrate normal flow void.

Paranasal sinuses are unremarkable.

IMPRESSION:

1. **Right phthisis bulbi with plaque like soft tissue in the posterior chamber of the right globe and thinned out right optic nerve.**
2. **12 x 18 mm heterogeneously enhancing focal lesion in the posterior chamber of the left globe with associated retinal detachment and vitreous hemorrhage. Left optic nerve is unremarkable. Findings are suggestive of residual disease.**
3. **Thickening of the gyri of the bilateral temporoparietal lobe with ill-defined interface of grey and white matter (R>L). Findings are suggestive of polymicrogyria pachygyria complex.**

Clinical correlation is necessary

DR. ANKUR GADODIA
MD (AIIMS), DNB, FRCR (UK)

saksham
IMAGING AND DIAGNOSTICS
A - 1/10, GROUND FLOOR & BASEMENT, SAFDARJUNG ENCLAVE
NEW DELHI - 110029, CONTACT - 011 - 40727900 / 09599464433
eMAIL:- info@sakshamimaging.com, http://sakshamimaging.com

MIS 2022-0134

PATIENT'S NAME: ARPITA SINGH	AGE/SEX: 2/F
REF. BY: DR. AIIMS	REG./UID: AAH5232
TEST NAME: 3T MRI SCAN - CEMRI HEAD & ORBITS	EXAM. DATE: 05-FEB-2025

CEMRI BRAIN AND ORBITS

STUDY PROTOCOLS:
MR IMAGING OF THE BRAIN WAS PERFORMED USING FLAIR, T1 AND T2 WEIGHTED AXIAL SECTIONS, AND CORRELATED WITH T2W SAGITTAL AND FLAIR CORONAL IMAGES. IMAGING OF ORBITAL REGIONS WAS PERFORMED USING CORONAL STIR, T1W AND T2W SECTIONS AND CORRELATED WITH T1W AND T2W AXIAL AND SAGITTAL IMAGES. POST CONTRAST SE T1 WEIGHTED IMAGES WERE ALSO OBTAINED IN CORONAL, SAGITTAL AND AXIAL PLANES. POST CONTRAST SE T1 WEIGHTED IMAGES WERE ALSO OBTAINED IN CORONAL, SAGITTAL AND AXIAL PLANES.

FINDINGS:

There is evidence of CSF cleft is seen in the bilateral temporo-parietal region with normal cortex – likely small close lip Schizencephaly.

There is ill defined altered signal intensity in the form of T2/FLAIR hyperintensity is seen involving the bilateral periventricular and peritrigonal region with mild prominence of bilateral lateral, third and fourth ventricles - likely sequelae of hypoxic ischemic encephalopathy.

Right eye ball is bulky in size and shows heterogeneously enhancing mass lesion measuring approx 28 x 25 mm in posterior chamber of right eye ball causing loss of anterior posterior differentiation and involvement of lens causing irregularity of the right eye ball.

There is heterogeneously enhancing mass lesion measuring approx 18 x 12 mm also seen in posterior chamber of left eye ball involving the retina.

Rest of the cerebral parenchyma appears normal in signal intensity with maintained grey and white matter differentiation.

Diffusion weighted imaging carried out does not reveal any area revealing hyperintense signal intensity with increasing 'b' values.

Both cerebellar hemisphere and brainstem appear normal in morphology and signal intensity. Cerebellopontine angle regions appear normal.

Basal ganglia and thalamic regions appear normal in signal intensity.

Ventricles are normal in shape, size and outline. Septum is in midline. Basal cisterns and sylvian fissures are normal.

Sellar and parasellar regions appear normal.

Bilateral optic nerves grossly appear normal.

Optic chiasma appears normal in contours and signal intensity, at present.

Bilateral cavernous sinuses appear normal.

Reported & Signed by: **Dr BHAVESH PATEL**

Disclaimer: It is an interpretation of medical imaging/diagnostic based on clinical data which is being provided in an electronic format which does any physical signatures. All modern machines/procedures have their own limitation. This is neither complete nor accurate; hence, findings should interpreted in the light of clinico-pathological correlation. This is a professional opinion, not a diagnosis. Not meant for medico legal purpose typographical error should be informed and report sent for correction within 7 days.

saksham
IMAGING AND DIAGNOSTICS
A - 1/10, GROUND FLOOR & BASEMENT, SAFDARJUNG ENCLAVE
NEW DELHI - 110029, CONTACT - 011 - 40727900 / 09599464433
eMAIL:- info@sakshamimaging.com, http://sakshamimaging.com

MIS 2022-0134

PATIENT'S NAME: ARPITA SINGH	AGE/SEX: 2/F
REF. BY: DR. AIIMS	REG./UID: AAH5232
TEST NAME: 3T MRI SCAN - CEMRI HEAD & ORBITS	EXAM. DATE: 05-FEB-2025

IMPRESSION: CEMR imaging of brain and orbits reveals:

- CSF cleft in the bilateral temporo-parietal region with normal cortex – likely small close lip Schizencephaly.
- Ill defined altered signal intensity in the form of T2/FLAIR hyperintensity is seen involving the bilateral periventricular and peritrigonal region with mild prominence of bilateral lateral, third and fourth ventricles - likely sequelae of hypoxic ischemic encephalopathy.
- Bulky right eye ball with heterogeneously enhancing mass lesion in posterior chamber of right eye ball causing loss of anterior posterior differentiation and involvement of lens causing irregularity of the right eye ball – likely retinoblastoma.
- Heterogeneously enhancing mass lesion in posterior chamber of left eye ball involving the retina – likely retinoblastoma.

Please correlate clinically

Dr. Sacchidanand Purkait Chief Consultant Radiologist	Dr. K. K. MISHRA Consultant Radiologist..	Dr. Bhavesh Patel Consultant Radiologist	Dr Rahul Bhartiya Consultant Radiologist

Reported & Signed by: Dr BHAVESH PATEL

दिनांक - Date

उपचार - Treatment

सोमवार
(53) Monday

NRC at 9am c̄ MRT Reports

Tues day
18/2/25
7th floor
NPO
8:00 AM

Date for EUA

Comp Tuesday

EUA

13.2.25

16/2/25

Date for EUA = ~~07/03/25~~
11/03/25

(62) - Patch RE
F/U on Tuesday

11/3/25 (BE)
EUA cancelled i/v/o URTI,
F/u c̄ peds consultation report to onco clinic ~~on~~ at 2pm on Monday / Thursday

Missed multiple EUA dates i/v/o
last chemo 11/20 - March 25.

नेत्र ईश्वरीय सर्वश्रेष्ठ उपहार है जिनका मनुष्य जीवन में दान करना परमश्रेष्ठ है।
इनकी पूर्ण रक्षा कीजिए ताकि ये अपनी रक्षा कर सकें।

Eyes are God's most precious gift to man kind and eye donation is the most noble deed.
Take full care of them so that they can take care of you.

05/04/25 (Rt) EORB
(Lt) IDRB — Staging EUA pending
(Cancelled twice i/v/o LRTI).

No fresh complaints. Afebr

Received cycle 9 HDCEV → Reassessment pending.

O/E Pallor(+) HR-90/m Chest-clear, NAD
RR-30/m CVS-S1S2 heard
CFT-2s NUS-3 gull-

04/04/25 7.9 7140 540 960

Adv

1) MRI Brain + contrast lesions
2) EUA date → RPC consultation.
3) Sibling screening
4) N/V OPD → 09/04/25 Wednesday 9am
5) RB gene testing

19

O/P Issue
... Vision ...
... redness over b/l lower limb resolving
Adv
1. rpt CBC
↓
if counts (N)
⇓
then stop iv antibiotics
2. ct. septran / betadine gargles
sitz bath as advised
3. N/w in daycare for R.M. TM
Adv
— Check Culture CBC
Stop AbK if ANC ...
F/U c rept CBC/LFT/R
On 5/4/25

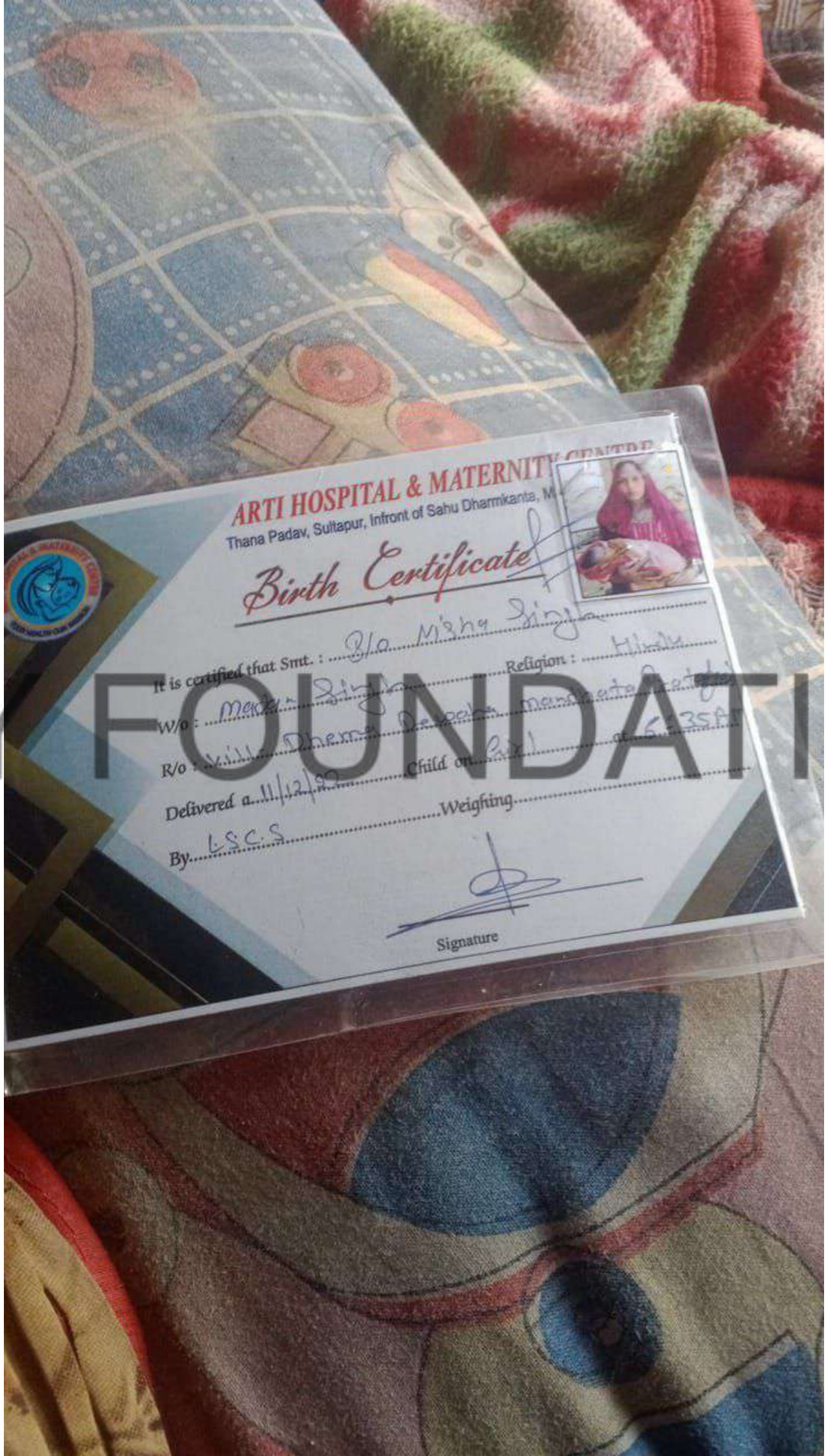


भारत सरकार
GOVERNMENT OF INDIA
मदन सिंह
Madan Singh
जन्म तिथि/ DOB: 01/01/1977
पुरुष / MALE
मेरा आधार,

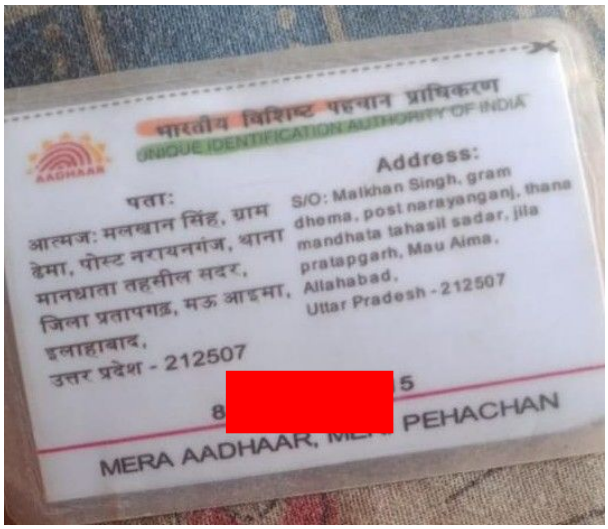
भारतीय विशिष्ट पहचान प्राधिकरण
UNIQUE IDENTIFICATION AUTHORITY OF INDIA
AADHAAR
पता:
आत्मज: मलखान सिंह, ग्राम देमा, पोस्ट नरायनगंज, थाना मानधाता तहसील सदर, जिला प्रतापगढ़, मऊ आइमा, इलाहाबाद, उत्तर प्रदेश - 212507
Address:
S/O: Malkhan Singh, gram dhema, post narayanganj, thana mandhata tahasil sadar, jila pratapgarh, Mau Aima, Allahabad, Uttar Pradesh - 212507
MERA AADHAAR, ME PEHACHAN