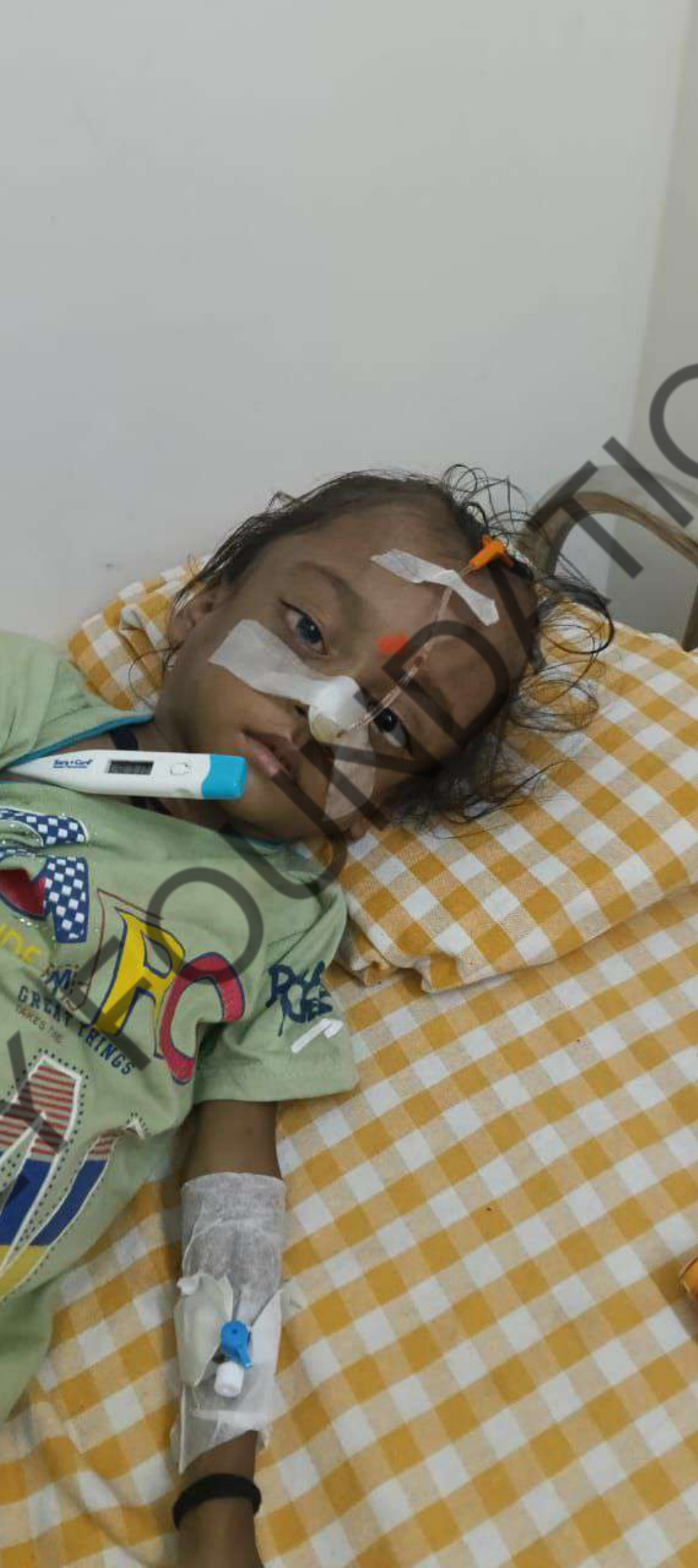
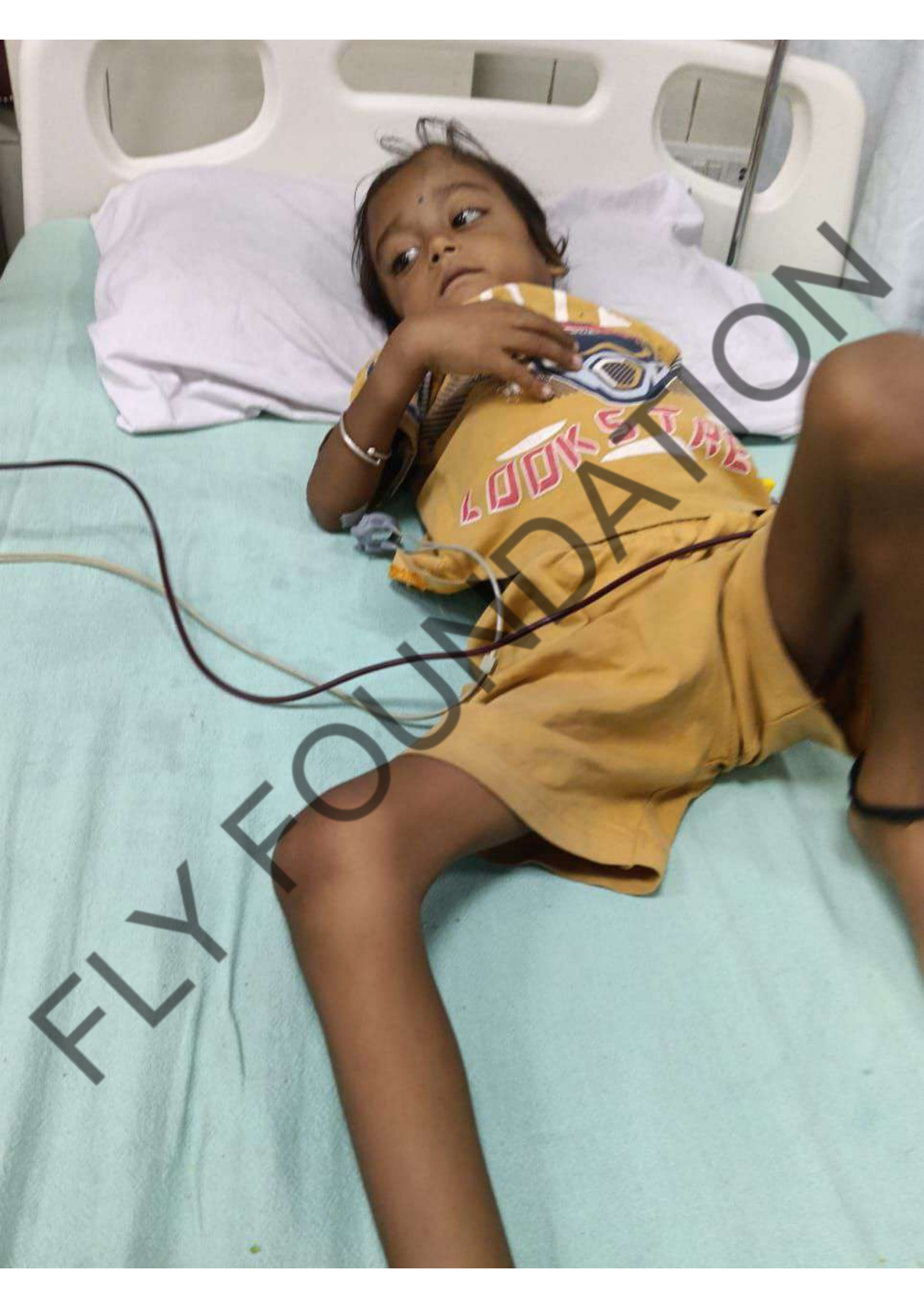
FLORIAN





Patient Details

Name : Aryam Raj

Age / Gender : 5 year M

Father's Name : Harje Ram Kumar

Address : Benar

Contact No :

POC / PCSC No.: 362/24

Diagnosis:

N.B

- Comellingshu
- Dr. Betadine gargle
  - Sitz bath
  - Personal hygiene
  - Thermometer
  - Danger sign explained
  - Blood donation
  - Sick card given
  - Accommodation st/24

NR

Remarks :

PICC Line Care

अगर आपके बच्चे को PICC Line Care लगी हुई है तो डे केयर के डॉक्टर से जरूर संपर्क करें।

⑤ to follow up in Peds Onco OPD  
 On POC clinic  
 3/12/24

*[Signature]*

30/11/24

- clo pain over the left eye.
- Oedema (+) over left eye.
- clo cold cough, looks tired.
- Parent consulting done regarding roots care, Nail care, Stix bath.
- On Septrox (alt)

Dr. VISHAKHA VARSHNEY  
 SR, Pediatric Oncology  
 Dept. of Paediatrics  
 AIIMS, New Delhi

Dr. SHASHI KUMAR  
 SR, Paediatric Oncology  
 Dept. of Paediatrics  
 AIIMS, New Delhi

QO metastatic NB7 @ follow up

⇒ MRI s/o extensive subdural deposits /  
 temporal lobe deposits  
 involving brain parenchyma  
 @ on-compression

RPC:

\* planned for Right side permanent haemostasis  
 ↓ G.A.

Scenario for @ Exposure Keratopathy

1<sup>st</sup> cycle: 2 more cycles OPEC-OJEC

↓  
 file assessment

\* no fever / cough / ~~nausea~~ / vomiting / abdominal pain /  
 loose stools / vomiting

CBC : 7.7  
 (20110)

4580  
 2570  
 70000

LFT/RFT: @

P.T.T @

30/12/24

Sent in POC clinic.

- child planned for (R) tarsorrhaphy (for exposure keratitis).

Sent from RPC for clearance.

Hack Hb < 7.

Transfused on 28/12/24

Rpt Hb: 8.2.

- child hemodynamically stable.  
- chest clear.

Plan:

1. Cleared from Ped Oncology side for Sx
2. To send iron profile on follow up visits.
3. R/w in RPC stat
4. OPD on 6/1/25 @ CBC 2pm POC clinic  
(Next chemo to plan if any delay in Sx)

8  
5/1/25

25/11/24

416

counselled on  
gargle/sitz bath  
personal hygiene  
c/o cold x 2 days.  
pain in both eyes  
x 2 days.

Hb - 5.5  
Plt - 50K.  
(protocol & MRI  
photocopy)

Metastatic HR NB / N-MYC status awaited

Received copies of OPEC-OPEC charts

No % fever / bleeding.  
manifestation

23/11/24  
55 4700 20000  
ANG-206-

% — Pallor (+)  
chd - clear NVR J.  
No features of HR

Adv/

Being sent to Pediatric casualty for PRBC transfusion

Ophthalmology review for exposure keratopathy

N/V → H/2/24 with reports of

(BC, LFT, RFT)



Dr. Pulisamy  
SE/Pediatric  
Senior Resident  
Department of Pediatrics  
All India Institute of Medical Sciences  
Anand Nagar, New Delhi-110029

23/11/24

counselled on

- Betadine gargle 4x
- sitz bath
- personal hygiene
- No fresh complaint on Septean A/D
- (photocopy of protocol & MRI)

Metastatic HR/NB / SAM / MYCN - awaited  
has Ⓡ INFP

→ received cycle test 2 cycles

→ last cycle on 22 13/11/24

- ~~no~~ fever
- no vomiting
- no cough/cold

ham ↓ anion

MRI → clinical

Signal intensity involving skull bones, base of skull, & associated extradural soft tissue component

HR: 110

RR: 28

PF: 11/11

RS: NE-B3 dia.

CV: S1S2 heard

PA: soft

CRS: ACS 15/11

deviation of < of mouth to Ⓡ.

→ Ⓡ eye unable to close

Ⓡ pallor (+) A dx

→ CBC / RFT / LFT today

→ MRI brain + orbit ~~to~~  
→ kept for RL discussion

→ Lt septum

fu on 23/11/24 at 2pm

at 2pm

To Rene  
for Pedrocco

17





अ० भा० आ० सं० अस्पताल / A.I.I.M.S. HOSPITAL  
बहिरंग रोगी विभाग / Out Patient Department

OK-94942  
All MS P=0



अस्पताल के अन्दर धूम्रपान बन्द है / SMOKING IS PROHIBITED IN HOSPITAL PREMISES

रक्त विज्ञान विभाग

UHID: 107830583



Dept No: 2024003027836

कमरा / Room  
C-217

Queue / संख्या  
N4

UPH: PCSC PAEDS

OPR-6

ARYAN RAJ

वर्तमान संख्या नं./O.P.D. Regn. No.

उम्र / Age

पता / Address

DR HARENDRA KUMAR  
SYDNEY / INDIA

80GARI, JAMLPUR, KHAGERA, BHAR  
Pt. C. INDIA

Ph

New Patient

General Rs 0



Reporting: 02:50:35  
02/10/2024

107830583

रिक्त / Diagnosis

Suspected Neuroblastoma

दिनांक / Date

41

उपचार / Treatment

10.10  
USG  
done guided biopsy dated as 7/10/24  
an FBE-CT dated 4/10/24  
CT head dated 25/10/24 → to be  
performed

Uc - 16/0.1

UA - 33

CRP - 91/3.9

H/PT - 52/31

ALP - 289

Ceruloplasmin - 5078

U-D - 13.50

7.2) 5700 (15.2 x 10<sup>3</sup>)  
2570  
7.2) 7000 (11.4 x 10<sup>3</sup>)  
3620

PT/INR (N)

637/10/220

Adv

• ORP CRAIN (57120) 6ml fat

• TW - 5/10/24



CLEAN AND GREEN AIIMS / एक का घों सफाई, स्वच्छता में जगह बन

अपदान-वीर्य का बहुमूल्य उपहार / ORGAN DONATION - A GIFT OF LIFE

O.R.B.O., AIIMS, 26588360, 26583444, www.orbo.org Helpline - 1960 (24 hrs service)

श्री० बाबीराम प्रसाद मेनन  
श्री० प्रो० अशोक कुमार

मेरा  
अस्पताल  
My Hospital  
menepatal@ipg.gov.in



16/11/24

Metastatic HR-NB / SAM / NMYC status awaited

Post 2# chemo OPEC → 12/11 - 13/11/24

No fresh issues

Wt gain of around 1 kg ⊕

Act

Cont GCsf as advised

f/u 2/12/24 - ROC 2pm ~ CBC  
RFI/RFI

RPC OPD for Mx of corneal ulcer

Diet as advised

Cont Septam

Expedite funds for ASCT - Shanti,  
pls explain

20/11/24

c/o metastatic HR-NB / SAM / NMYC status awaited

→ post 2# chemo OPEC


• no fresh issues

ophthal evaluation

⇒ (B) exposure to chemotherapy & logoptical med



अ० भा० आ० सं० अस्पताल / A.I.I.M.S. HOSPITAL  
बहिरंग रोगी विभाग / Out Patient Department



SMOKING IS PROHIBITED IN HOSPITAL PREMISES

बाल चिकित्सा विभाग  
UHID-107830583  
Dept No: 20340030027301  
ARYAN RAJ

कमरा / Room: C-210  
Queue संख्या: N6  
Unit-1, POC

OPR-6

S/O HARENDRA KUMAR  
BY DEEPTI KAWATRA  
POISARI JAMALPUR KHAGERA BHAR  
PIN-826004  
New Patient  
General Rx 0

MON 08  
Reporting: 014245  
30/09/2024

Age

Address

Pediatric  
107830583

Pers/Diagnosis

(L) Suprarenal mass - ↓ evaluation. (? Metastatic neuroblastoma)

Time/Date

Treatment

fever (on/off) → 9 months  
% Abdominal pain → 3 months  
US abdomen (outside)

BP ↑  
11 Kg  
B/p proptose of eyes → 2 months  
(L) Suprarenal mass with  
fmy calcification 4.5x4cm

Sweating at night  
blepharospasm angle  
causing ↓  
Multiple enlarged retroperitoneal,  
mesenteric lymph nodes

BP →  
• Outside  
• BMA - dilute d.  
US abdomen  
CT abdomen - to be discussed

PEP (CI) done on 4/10/24  
MIBA to be explained  
Mass biopsy dated 07/10/24  
Multiple enlarged retroperitoneal,  
mesenteric lymph nodes

Multiple small nodules seen



CLEAN AND GREEN AIIMS / एकमात्र का पत्ती संकल्प, स्वच्छता से बनाया कल्प

अंगदान जीवन का बहुमूल्य उपहार / ORGAN DONATION - A GIFT OF LIFE

O.R.B.O., AIIMS, 26588360, 26583444, www.orbo.org Helpline - 1060 (24 hrs service)

B/p पालीमोरा  
अस्पताल  
AIIMS  
mumbaihospital.nhp.gov.in

27/4/24

consulted  
on ganglion/pterygium  
personal hygiene  
of pain at eye  
X3 days  
on Septem 4/D.

C10 Metastatic HR Neuroblastoma

N - HNC status awaited

⊕ (R) in facial nerve palsy

Hx: S/S on 25/11/24

→ received PRBC transfusion on  
25/11/24

26/11/24

4500  
2250  
9000

RFT/LEFT @

U/A → 6:1

→ pain in ⊕ eye  
BL proptosis

→ no fever

→ HR: 110

RR: 25

PT: 110

→ R - NB = BC dead

CVS = S1S2 heard

PA: right

CVS: aciculate

BL proptosis

→ deviation of angle of  
mouth to ⊕ side

→ difficulty in closing  
in ⊕ eye

Adv

MRI added for discussion → fu tomorrow in 217 room

films

NIV

28/11/24

2pm

PRC clinic

Dr Rema  
Dr Tedesco

to start  
→ T.

Allopurinol 100mg

1/2 1/2 1/2

19

Pr Rema  
Dr Tedesco

U/A → 6:1

start

2024/12/2

11/12  
discussion  
1/24  
MRI - Brain

(C) C10 Metastatic NB / (B) Facial nerve Palsy Bone

- diffuse all calvarium Involvement, Both Sides  
Intra cranial & Extra cranial  
Subdural deposits (C)

- (2) Temporal Bone - large Metastatic deposits  
Involves the Brain Parenchyma -  
also compressing CN at the cereb.

- B12 728<sup>u</sup> Nerve involvement at CP angle due to deposits

- C12 ~~bone~~ parotid gland & surrounding tissue involvement  
mandibular ramus also involved.

C10/11/12 Dr Raehna man

to give 2 cycles of OPBC - A160  
Response assessment after that

PET-CT after 2 cycles  
mother Replained regarding the prognosis of this

(5)  
25/11/24  
- clo pain  
left eye.  
- Oedema (L)  
- clo cold cough  
- Patient cannot  
regulating roads  
Nail can, St3  
- On Septans (L)

3<sup>rd</sup> eye

cbc : 7.7  
(21110)

left eye

1/24

Metastatic HR-NB / SAM / NAK status awaited

Post 2# chemo OPEC → 12/11 - 13/11/24

No fresh issues

wt gain of around 1 kg (out)

Cont best as advised

f/u 2/12/24 - ROC 2pm = CBC

RPC OPD for Mx of corneal ulcer

Diet as advised

Cont Septam

Expedite funds for ASC - Shanti; pls explain

*Shanti*

20/11/24

c/o metastatic HR-NB / SAM / average status awaited

→ post 2# chemo OPEC

\* no fresh issues

optical evaluations

⇒ (A) exposure to retinopathy & (B) myopia

25/11/24

416

Metastatic HR NB / N-MYC status awaited

counselled on  
gargle/sitz bath  
personal hygiene  
c/o cold x 2 days.  
pain in both eyes  
x 2 days.

Received cycle of OPEC-OJEC chemo

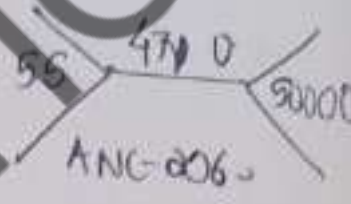
Hb - 5.5

Plt - 50K.

(Photocopy & MRSA  
photocopy)

No % fever / bleeding  
manifested

23/11/24



% ——— Pallor

child - (dys-NVB)

No features of HR

Adv/


Being sent to Pediatric casually for PRBC transfusion

Ophthalmology review for exposure keratopathy

N/V → ~~9~~/12/24 with reports of

(BC, LFT, RFT)

*Dr. Pulisamy*  
Senior Resident  
SR / Pediatric  
Chitambar



LC2611241298 107838583



LH2611240851 107838583



ARYANRAJ

28/11/24

(1)

C10 Metastatic NB / (B) Facial nerve

Palsy

Bone

RC discussion

- diffuse all calvarium Involvement, Both sides  
Intra cranial & Extra cranial

28/11/24

MR - Brain

- Subdural deposits (1)

- (2) Temporal Bone  
large Metastatic deposits  
Involving the Brain  
Parachyma.  
& also compression  
at the 4th nerve

- B12 7, 8, 9th nerve involvement  
at CP angle due to deposits

- B12 ~~to~~ parotid gland.  
& surrounding tissue  
involvement

↳ Mandibular ramus also involved.

C/D/W Dr Rachel Mann

Plan

- (1) to give 2 cycles of OPBC - A'EO
- (2) Response assessment after that
- (3) PET-CT after 2 cycles
- (4) Mother explained regarding the prognosis of DS

9/11/24 → ① DAYCARE

• clinically no neuro deficits

bone pains persisting ⊕

• on no feeding

was tentatively slotted

for cisplatin cycle → no beam counts available

last pt - 49k  
3110k

Advise

② Repeat CBC  
RFTs

③ Reslotted to 12/11/24

④ pt on OPD 9/11/24 wed AM

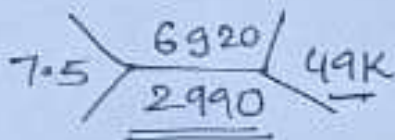


2/11/24

HR-mets NB | SAM | (R) corneal ulcer

(R) OJec @ 75% dose → 22/10/24.

31/10/24



O/Cr = 9/0.5

had (C) ear ache

↓  
visited casually

↓  
ENT :- (L) otomycosis ⊕  
(31/10/24). fluid behind TM  
e bulge.

Adv :- candid e/d 2°  
TDS x 2 weeks  
(not taking)

Minor OT → cleaning done  
by ENT team.

O/E HA = 121/min

KA = 28/min

SAM ⊕

Multiple CX LAD

B/C proptosis

(R) corneal ulcer ⊕  
dry lustine ker hair.

① 7/c Septican alternate  
day

② Solwan e/d 2° TDS  
x 3 days

③ Candid e/drop 2° TDS  
x 2 weeks

④ Refresh e/d 1° B/L eye  
QID TO

continue

98: used vision in left eye

? 2° dural & periorbital deposits

? 0 no involvement

c/d/w Prop R sets

Adv

c-to con kids Kindly help

1. MRI for orbit for further glaucoma

Conclude N ←

2 to evaluate down optical

BP → 120/80 normal

2 Myv on 23/11/24  
9AM

u. add tab Amblyopire (2.5mg)  
1/2 tab BO

at  
sft

~~120/80~~

09/11/24

Metastatic Neuroblastoma / SAM / Correct ulcer

→ weight gain ⊕

• swelling orally with  
& by NV

↓  
no vomiting / loose stools / abdominal pain

→ swelling over leg

• Pt. red, epinephrine region

• mild tenderness

IMU

CBC: 7.4 (10/11) 6820 3340 160K

Adm

1. proceed to next chemor cycle

LFT/RFT ⊕

ALP: 216 ↑

2. chemos started on protocols  
(dated for 12/11)

3. funds to be arranged for  
transport

4. refer to RPC for evaluation  
& management of correct ulcer

S. N/V on 16/11/24

9 AM

27/11/24

coremelled  
on gargle/salt bath  
personal hygiene  
of pain at eye  
X3 days  
on Septan 4/D.

C10 Metastatic HR Neuroblastoma  
N-MHC status awaited  
T (R) IN facial nerve palsy. T (L) NFF  
Hw: 5.5 on 23/11/24  
→ received PRBC transfusion on  
25/11/24

→ pain in eye  
BL proptosis.

→ no fever

→ HR: 110

RR: 26

PPHT/H

→ BS: AB = BS clear

C/S = S/S 2 heard

PA: soft wt

CNS: acsistls

BL proptosis

→ deviation of angle of  
mouth to (L) side

→ difficulty in closing  
in (R) eye

Adx

HR1 added for discussion → fu tomorrow in 217 room

firm  
NIV

28/11/24

9:20 AM  
P/S Clinic

Dr Reme

Dr Pedanco

to start

→ T

Allopurinol 100mg

1/2

1/2

1/2

19

Dr Reme  
Dr Pedanco

u.a → 6.1

start



NO IS PROHIBITED IN HOSPITAL PREMISES

बाल चिकित्सक विभाग  
 UNID: 107630583  
 ADHA ST: 2473-8537-1985  
 Dept No: 20240020027808  
**ARYAN RAJ**

कक्ष / Room: C-211  
 कक्षा / Section: F36  
 Unit-II Paediatrics

OPR-6

डॉ. हार्दिका कुमार  
 MD (RD) / MCh (P)  
 COCHIN, JAMALPUR, KHAGERA, BHAR  
 Ph.D. I.D.A.  
 Ph: 787069000  
 Follow Up Patient  
 General Rx 0



ब. नं. वि. एडमिशन नं. / O.P.D. Regn. No.

आयु / Age

पता / Address

रिपोर्ट / Diagnosis

(mets skull/plena)  
 ? Metastatic Neuroblastoma & evaluation

दिनांक / Date

उपचार / Treatment

• PET CT → done on 4/10 → PET discussion added

• USG guided Bx → 7/10/24 (gun arranged)

• B/c BMA + Bx → 8/10/24 ✓

⊗ CT Head + Chest → 25/10/24

Scheduled Bx 31/10/24 [daycare team to expedite]

O/E

SAM ⊕ wt/ht → -4.5%.

B/L proptosis (L > R).

facial palsy ⊕

multiple skull swellings ⊕

RC discussion :- ⊕ suprarenal solid/cystic mass displacing kidney inferiorly, encasing renal artery, crossing midline, no intraspinal collection

⊗⊗ B/c pleural deposits ⊕

CLEAN AND GREEN AIIMS / एम्स को प्यारी रखना, रोग से काया बचाना  
 अंगदान - जीवन को बहुमूल्य उपहार / ORGAN DONATION - A GIFT OF LIFE

O.R.B.O., AIIMS, 26588360, 26593444, www.orbo.org Helpline - 1060 (24 hrs service)



maiseepatal.aiims.gov.in

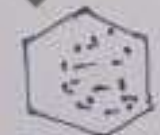

अस्पताल का लोगो  
 गणपति

LD  
 11-2 leg  
 emegatti  
 added.

LDH = 480  
 Ferritin > 5000

1/10  
 7-2  
 7090 / 1.14L  
 5/40  
 INR = 0.99



Tender &

FEV



अ० भा० आ० सं० अस्पताल / A.I.I.M.S. HOSPITAL  
 बहिरंग रोगी विभाग / Out Patient Department  
 अस्पताल के अंदर धूम्रपान बंद है / SMOKING IS PROHIBITED IN HOSPITAL PREMISES

OK-94942  
 All MS P=0

5625710386  
 107830273

रोगी विवरण / Patient Details  
 UHID: 107830583



Dept No: 2024000027638

ARYAN RAJ

कमरा / Room  
 C-217

Queue / संख्या  
 N4  
 UHID, PCSC RAEDS

OPR-6

DR HARENDRA KUMAR  
 SYDM SD / M/FR  
 DOGAR, JAMALPUR, KHAGERIA, BHAR.  
 PIN: INDIA  
 Ph: 7870686000  
 New Patient

General Rx 0



Reporting: 02:50:38  
 53103024

वर्गीकरण संख्या / O.P.D. Regn. No.

उम्र / Age

पता / Address

रोग / Diagnosis

Suspected Neuroblastoma

दिनांक / Date

41

10/10

उपचार / Treatment

USG done  
~~done~~ guided biopsy dated as 7/10/24  
 on PET-CT dated 4/10/24  
 CT head dated 25/10/24 → to be  
 performed

Ulc - 16/0.1

UA - 33

Crab - 91/3.9

Cr/PT - 52/81

Cr/PT - 282

Creatinine - 5.78

Cr - 13.50

2)  $\frac{5700}{2570}$  (150x10<sup>3</sup>) PT/WR (N)  
 4)  $\frac{7000}{3620}$  (114x10<sup>3</sup>)  
 5/10/24

Adv

• CRP chain (57/24) 5ml stat

• RW - 5/10/24



CLEAN AND GREEN AIIMS / एम का परी सकार, अस्पताल में जला बन्द

अंगदान-वीरान का बहुमूल्य उपहार / ORGAN DONATION - A GIFT OF LIFE

O.R.B.O., AIIMS, 26588360, 26593444, www.orbo.org Helpline - 1060 (24 hrs service)

किसी भी प्रकार का प्रयोग न करें  
 Do not use for any purpose

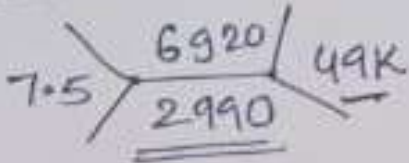
भारतीय अस्पताल  
 All India Institute of Medical Sciences  
 New Delhi

2/11/24

HR-mets NB | SAM | Ⓡ corneal ulcer

Ⓡ OJec @ 75% dose → 22/10/24.

3/10/24



V/Cr = 9/0.5

had Ⓡ ear ache

↓  
visited casualty

↓  
ENT -- Ⓡ otomycosis Ⓡ

(3/10/24). fluid behind TM  
c bulge.

Adv. Candid e/d 2°  
TDS x 2 weeks  
(not taking)

minor OT → cleaning done  
by ENT team.

O/E HA = 12/1/min

RA = 28/1/min

SAM Ⓡ

multiple Cx LAD

B/L proptosis

Ⓡ corneal ulcer Ⓡ

dry lustre less hair.

plan

① T/c Septtran alternate  
day

② Soluwan e/d 2° TDS  
x 3 days

③ Candid e/d 2° TDS  
x 2 weeks

④ Refresh e/d 1° B/L eye  
QID TO  
continue

Advice DLW - Prof. Rachma Selli Masary

08/09/24

1. Sp. Paracetamol (25mg/5ml) 5ml PO SOS

2. Sp. Ibuprofen 2.5ml PO two times daily

3. Pain & palliative medicine consultation (Room no. 60 / IRCH).

4. NG insertion - MCH Daycare.

NG feeds 60ml Q2H 3 feeds followed by 80ml Q2H

- pain
- NG feeds
- CT scan
- CDCE

5. CDCE scan tomorrow

Expedite biopsy

8/10/24

6. CDCE chemo.

7. Date for BMA/Biopsy.

8/10/24

8 - N/V → 03/10/24 PLSC @ 2pm

8/10/24

QD Echo → MIB SPA  
Dr R. Masary

7.3 6050 85000  
ANC-4000

P/INR 15.1  
aPTT 31

U/G 16/0.1 U. aud-3.3

Ca/P 9.1/3.9 Na<sup>+</sup>/K<sup>+</sup> 134

TB/PB -0.3/0.1 AGI/ALP -50

Kreatinin - 5098

✓ INEL TIME RECEIVED  
01/10/24  
1010

8/10/24

Dr. NIKSUNA SUDHARMA P.R.  
DHA Resident  
Pediatric Oncology  
AIIIMS, New Delhi



To,  
The Cankid's

22/10/24

Kindly assist this patient for

- ① inj. CARBOPLATIN [350mg/vial] ~ ① vial
- ② inj. ASCORBA [100mg/vial] ~ ① vial
- ③ inj. CYCLOPHOSPHAMIDE [200mg/vial] ~ ③ vial
- ④ inj. MESNA [200mg/vial] - ② vial
- ⑤ inj. VINCRISTINE [1mg/vial] - ① vial
- ⑥ inj. ASCA [300mg/vial] ~ ① vial

Nikita

भारत सरकार

GOVERNMENT OF INDIA



फूल कुमारी

Phool Kumari

जन्म तिथि/ DOB: 13/05/1998

महिला / FEMALE



8952

मेरा आधार, मेरी पहचान



भारतीय विशिष्ट पहचान प्राधिकरण  
UNIQUE IDENTIFICATION AUTHORITY OF INDIA

पता:

अर्धांगिनी: हरेराम कुमार,  
अट/पोस्ट- बडी मलिया, वार्ड  
न-04, मोलिया, खगडिया,  
बिहार - 851203

Address:

W/o Haream Kumar, at/post-  
Badi malia, ward no-04, Molia,  
Bihar - 851203

8952

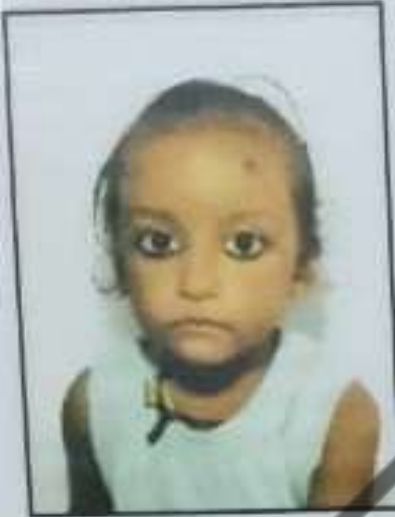मेरा AADHAAR, MERI PEHACHAN



सत्यमेव जयते

भारत सरकार

GOVERNMENT OF INDIA



आर्यन राज

Aryan Raj

जन्म तिथि/DOB: 2019

पुरुष/ MALE

XXXX XXXX 6424

VID : 9101 7354 1743 4896

मेरा आधार , मेरी पहचान